PSM
Veterinary Research

Research Article 2026 | Volume 11 | Issue 1 | 28-36

Open Access

Article Information

Received: October 24, 2026

Accepted: November 7, 2026

Published: November 24, 2026

Authors' Contribution

FAMQ: conceived and designed the study. MAAQ, AA, AA, EA, OA: performed the experimental work, data collection, and analysis. FAMQ: drafted the initial manuscript. NMAH: performed data verification, extensive rewriting, and language editing, followed by a critical review of the entire manuscript. EFS: reviewed the final draft of the manuscript for publication. HSG and EASA: reviewed the draft of the manuscript. All authors read and approved the final manuscript.

Citation

Al Hamdani, N.M.H., Moqbel, F.S., Qasim, M.A.A., AL-Salami, A., Al-Kawli, A., Al-Kawli, E., Al-Awadi, O., Shamsan, E.F., Al-Shaibani, E.A.S., Gumaih, H.S., 2026. Impact of Testosterone Administration on Gentamicin-Induced Endocrine Disruption and Testicular Toxicity in Adult Male Rabbits. PSM Vet. Res., 11(1): 28-36.

***Correspondence**

Nada M. H. Al Hamdani
Email:
n.alhamdani@su.edu.ye

Possible submissions

Submit your article

Impact of Testosterone Administration on Gentamicin-Induced Endocrine Disruption and Testicular Toxicity in Adult Male Rabbits

Nada M. H. Al Hamdani[1]*, Fahmi S. Moqbel[2], Mohammad A. A. Qasim[2], Ahlam AL-Salami[2], Ameera Al-Kawli[2], Eman Al-Kawli[2], Ola'a Al-Awadi[2], Ebtisam F. Shamsan[1], Elham A. S. Al-Shaibani[1], Hussein S. Gumaih[1]

[1]Department of Biological Sciences, Faculty of Science, Sana'a University, Sana'a, Yemen.
[2]Biology Department, Faculty of Applied Sciences, Thamar University, Thamar, Yemen.

Abstract:
Gentamicin is an effective aminoglycoside antibiotic widely used to treat bacterial infections. However, its use may be associated with adverse effects, including reproductive toxicity. This study aimed to evaluate the effects of testosterone administered alone or in combination with gentamicin on serum luteinizing hormone (LH) and follicle-stimulating hormone (FSH) levels and testicular histopathology in adult male rabbits. Twenty adult male rabbits were randomly divided into four groups (n=5/group). G1: control group, G2: gentamicin-treated group (40 mg/kg bw), G3: testosterone-treated group (15 mg/kg bw), G4: testosterone + gentamicin-treated group (15 and 40 mg/kg bw, respectively). Treatments were administered intramuscularly (IM), 5 days per week for one month. Serum LH and FSH levels were measured, and testicular tissues were examined histologically. Rabbits treated with gentamicin showed increased serum LH ($P<0.05$) and FSH ($P<0.01$) levels compared to the control. Testosterone alone significantly decreased LH ($P<0.05$) and FSH ($P<0.05$) levels compared to the control. Combined administration of testosterone and gentamicin resulted in the greatest increase in LH ($P<0.01$) and FSH ($P<0.001$) levels compared with the control and gentamicin-treated groups. Histopathological examination revealed marked structural alterations in testicular tissues following gentamicin exposure. In the combined-treated group, no histological protection against gentamicin-induced testicular injury was observed. Testosterone administration did not show a protective effect against gentamicin-induced testicular toxicity under the conditions of this study. The persistent testicular alterations in serum LH and FSH levels following combined treatment suggest disruption of testicular structure and reproductive endocrine function.
Keywords: Gentamicin, Testosterone, Testicular toxicity, rabbits, LH, FSH, Histopathology.

Scan QR code to visit this journal.

©2026 PSM Journals. This work at PSM Veterinary Research; ISSN (Online): 2518-2714, is an open-access article distributed under the terms and conditions of the Creative Commons Attribution-Non-commercial-NoDerivatives 4.0 International (CC BY-NC-ND 4.0) licence. To view a copy of this licence, visit https://creativecommons.org/licenses/by-nc-nd/4.0/.

INTRODUCTION

Antibiotics play an important role in the treatment of bacterial infections and have contributed substantially to improving clinical outcomes (Ashraf and Iqbal, 2020; Ashraf *et al.,* 2020; Iqbal and Ashraf, 2018). Gentamicin, a broad-spectrum aminoglycoside antibiotic, is widely used in clinical practice because of its effectiveness against various bacterial infections (Hamad *et al.*, 2023). However, its therapeutic application may be limited by adverse effects, particularly when it is administered at higher doses. Gentamicin-induced toxicity in the kidneys and other tissues, and increasing attention has been directed toward its possible effects on male reproductive system (Abdelrahman and Abdelmageed, 2020; Baradaran *et al*., 2014; Taha *et al.,* 2023).

Testes are important reproductive organs responsible for spermatogenesis and testosterone production. Exposure to toxic substances, including gentamicin, may affect testicular tissue and interfere with the normal organization of spermatogenic cells, causing alterations and disruption of spermatogenesis in the seminiferous tubules and changes in sperm-related parameters (Aly and Hassan, 2018; Khaki *et al.,* 2009; Taha *et al.*, 2023).

Oxidative stress has been suggested as one of the mechanisms involved in gentamicin-induced tissue injury. This occurs when the production of reactive oxygen species exceeds the capacity of the antioxidant defense system, resulting in damage to cellular lipids, proteins, and nucleic acids. The testes are susceptible to oxidative damage due to the high content of fatty acids in their cellular membranes. Gentamicin-associated oxidative damage has been investigated in different experimental tissues and animal models (Hong *et al*., 2006; Baradaran *et al.,* 2014; Hamad *et al*., 2023).

Previous studies have demonstrated that gentamicin can impair sperm motility, reduce reproductive organ weight, and cause apoptosis of testicular tissues, eventually resulting in testicular failure (Keogh *et al*., 2017; Aly and Hassan, 2018). Recent studies have provided further evidence of gentamicin-induced reproductive toxicity. Badr *et al.* (2025) reported significant reductions in serum testosterone and luteinizing hormone (LH), accompanied by decreased total antioxidant capacity and increased myeloperoxidase activity in testicular tissue. More recently, Celebi *et al.* (2026) demonstrated that gentamicin-induced testicular injury was associated with reduced serum testosterone levels and sperm motility, increased lipid peroxidation, impaired antioxidant defenses, and enhanced apoptotic activity. These findings highlight the involvement of oxidative stress and apoptosis in gentamicin-induced testicular injury.

Testosterone is the primary androgenic and anabolic steroid hormone in adult males. It plays an essential role in the development, growth, and maintenance of the testes and accessory reproductive organs, and in the development of secondary sexual characteristics, including increased muscle and bone mass and deepening of the voice (Hall and Hall, 2021). Furthermore, prolonged supraphysiological doses of testosterone have been shown to induce adverse histological changes in testicular tissue and suppression of the hypothalamic-pituitary-gonadal axis in male rats, due to atrophy of the germinal epithelium and Leydig cells (Shokri *et al*., 2014; Hashimi *et al*., 2025).

The non-medical use of testosterone and other anabolic-androgenic steroids (AAS) has also been reported among athletes and individuals seeking to increase muscle mass, physical performance, and strength. However, non-medical use is associated with significant adverse effects on the male reproductive system, including hypogonadism, testicular atrophy, and impaired spermatogenesis (Wu and Kovac, 2016; Beaver *et al*., 2008; Hartgens and Kuipers, 2004). AAS abuse has also been linked to cardiovascular complications, including hypertension, abnormal renal function, and heart failure (Hartgens and Kuipers, 2004; Herlitz *et al.,* 2010; Nieschlag and Vorona, 2015). At the cellular level, supraphysiological testosterone administration may increase oxidative stress by enhancing reactive oxygen species (ROS) production and suppressing antioxidant gene expression, leading to lipid peroxidation and damage (Beaver *et al.,* 2008). Similarly,

gentamicin-induced oxidative stress via free radical production and lipid peroxidation has been reported to damage spermatozoa and reduce sperm count and motility (Khaki *et al.,* 2009; Taha *et al.,* 2023). This study aimed to evaluate the effects of exogenous testosterone administration, alone and in combination with gentamicin, on serum LH and FSH levels and testicular histopathology in adult male rabbits.

MATERIALS AND METHODS

Chemicals

1- Testosterone was supplied by Ibin Hayan pharmacy, Sana'a, Yemen. The trading name of testosterone is Testoki testosterone, Sanzyme Company.

2- Gentamicin antibiotic was supplied by Sam Pharmacy, Sana'a, Yemen, and produced by KRKA.

Experimental animals

Twenty adult male rabbits (800–1500 g) were obtained from a local breed and maintained in individual cages in the animal care center of the Biology Department, Faculty of Applied Sciences, Thamar University. Animals were maintained under normal temperature and light cycles, given water and food *ad libitum,* and kept under these conditions for 4 weeks prior to the commencement of the experiment. The study protocol was approved by the Animal Ethics Committee of the Biological Science Department, Faculty of Science, Sana'a University (ethical code: BAHSS101). This study was conducted in accordance with the ARRIVE guidelines.

Twenty rabbits were weighed and randomly divided into four groups (five rabbits in each group) as follows:

a) **Group I (Control):** Rabbits received 1 ml distilled water.

b) **Group II:** Rabbits treated with 40 mg/Kg body weight (bw) gentamicin antibiotic.

c) **Group III:** Rabbits treated with 15 mg/Kg body weight (bw) testosterone hormone.

d) **Group IV:** Rabbits treated with 15gm/kg g/kg bw testosterone hormone followed by 40 mg/kg bw gentamicin antibiotic.

Rabbits were administered intramuscular (IM) doses of testosterone and gentamicin 5 days a week for one month.

Blood collection

At the end of the experimental period, rabbits were fasted for 10 hrs. At the end of the experimental period, rabbits were fasted for 10 h. Rabbits were euthanized by slaughtering, and blood samples were collected by heart puncture in non-heparinized tubes, centrifuged at 3500 rpm/min for 5 minutes, serum samples were separated and stored at 4°C to assess LH and FSH levels using standard ELISA-based techniques according to the manufacturer's instructions at the laboratories of Thamar General Hospital, Thamar city.

Histological examination

At autopsy, testicular specimens were collected from all animals, rinsed with normal saline, and fixed in 10% formalin for 24 hours. Tissues were dehydrated in graded ethanol, cleared in xylene, embedded in paraffin, and sectioned at 5 µm thickness, stained with hematoxylin and eosin, and examined under a light microscope. Histological changes were documented and photographed using a digital imaging system. All procedures followed standard histological techniques (Bancroft and Gamble, 2008; El-Sayyad *et al.*, 2009).

Statistical analysis

All data are expressed as mean ± SE. Statistical analysis was performed using one-way analysis of variance (ANOVA) using SPSS Version 22, followed by Tukey's multiple range test with a minimum significance level of $P < 0.05$.

RESULTS

Serum levels of FSH and LH hormones

Table 1 shows the effect of gentamicin and testosterone on serum levels of FSH and LH in male rabbits. Administration of gentamicin alone (GII) caused a significant increase in both FSH (P<0.01) and LH (P<0.05) serum levels compared to the control group (GI). In contrast, the testosterone-treated group (GIII) exhibited a significant decrease in FSH (P<0.05) and LH (P<0.05) serum levels compared to GI. The combined treatment with testosterone followed by gentamicin (GIV) produced a significant increase in FSH (P<0.001) and LH (P<0.001) levels compared to both GIII and G1.

Table 1. Effect of testosterone against gentamicin toxicity on FSH and LH serum levels in adult male rabbits.

Group (n=5/group)	FSH serum levels (mIU\ml) (Mean ± SE)	LH serum levels (mIU\ml) (Mean ± SE)
Control (GI)	0.16±0.05	1.80±0.01
Gentamicin treated group (GII) (40 mg/ kg bw)	0.32±0.08^{a**}	1.87±0.02 ^{a*}
Testosterone-treated group (GIII) (15 mg /kg bw)	0.12±0.04^{a*}	1.72±0.01 ^{a*}
Testosterone + Gentamicin treated group (GIV) (40 mg/ kg bw + 15 mg /kg bw)	0.48±0.13^{b**}	2.25±0.16 $^{a,b\ (***)}$

Mean ± SE values in each column were compared using one-way ANOVA followed by Tukey's post-hoc test. Means with the same superscript letters are significantly different. (a) letter indicates comparison to the control, and (b) letter indicates comparison to testosterone. *p < 0.05; **p < 0.01; and *** p< 0.001

Histological examination

The cross-sections of rabbit testes in the control group showed seminiferous tubules separated by a thin intratubular connective tissue containing Leydig cells. Seminiferous tubules included spermatogenesis with a normal arrangement of spermatogenic cells with an intact basement membrane. The spermatozoa were found in the lumen as well as attached to Sertoli cells (Figure 1a, b). The testes of rabbits treated with gentamicin (40 mg/kg bw) showed loosely packed connective tissue stroma around the seminiferous tubules with regressed Leydig cells, atrophic tubules, disorganization and degeneration of the spermatogenic cells, congested blood vessels, and vacuolization (Figure 1c, d). The spermatogenic cells appeared less in number and most of the spermatocytes and spermatids were degenerated (Figure 1c, d). Many spermatocytes were exfoliated into the lumen in some of the tubules, and large vacuoles appeared in the seminiferous tubules and congested blood vessels were found in-between the seminiferous tubules (Figure 1e).

The testis of rabbits treated with testosterone (15 mg/kg bw) showed normal architecture with normal seminiferous tubules (Figure 1 f, g). Gentamicin (40 mg /kg bw) + testosterone (15 mg /kg bw) treatment resulted in persistent tubular degeneration (Figure 1 h, i).

DISCUSSION

The present study aimed to evaluate the biochemical and histopathological effects of testosterone and gentamicin, administered alone or in combination, on the testes of adult male rabbits. The results demonstrated that both agents produced significant alterations in serum gonadotropin levels (LH and FSH), accompanied by structural damage to the seminiferous tubules, with the most pronounced injury observed in the group co-administered testosterone and gentamicin.

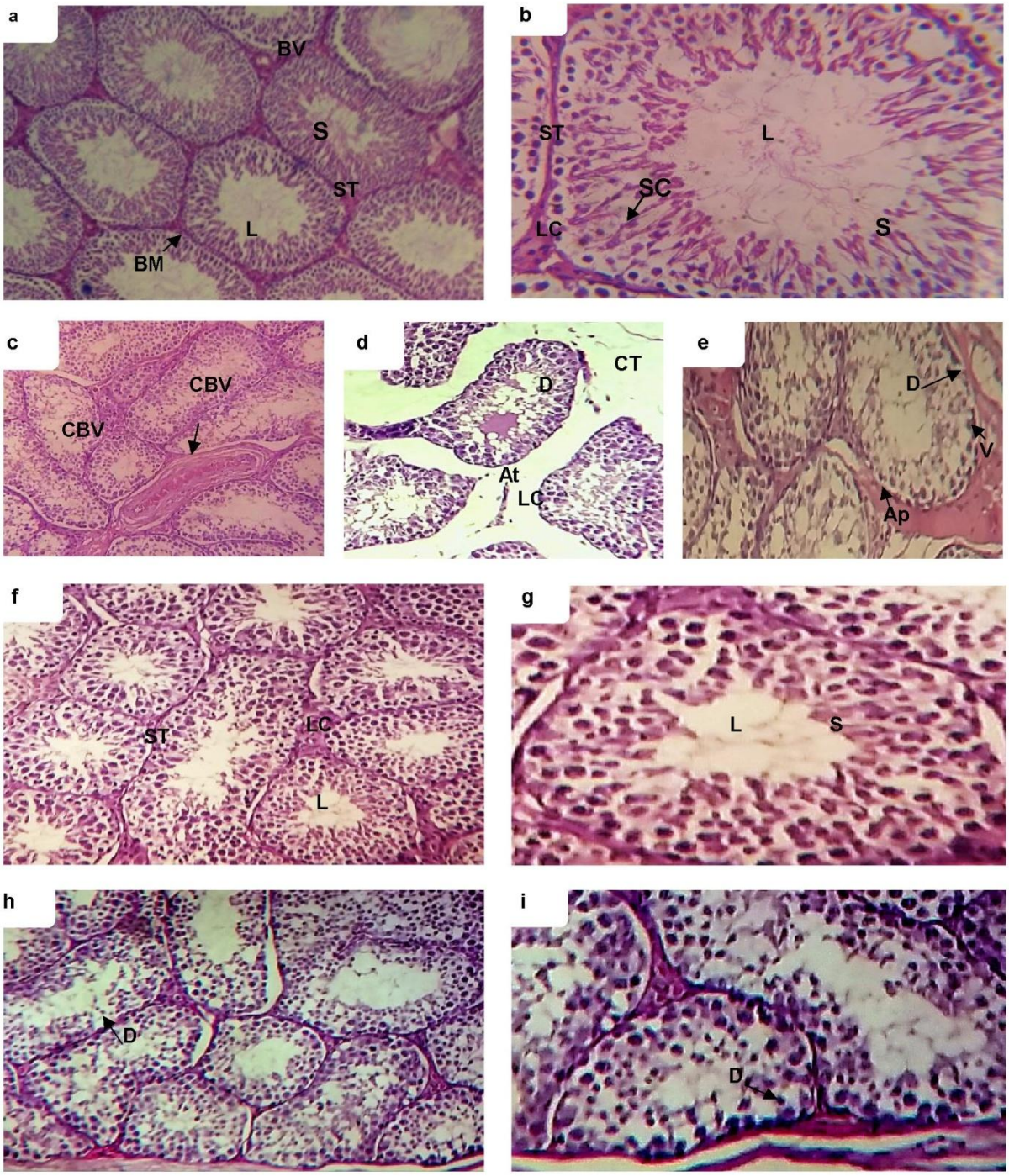

Fig. 1 (a-i). Histological photomicrographs of rabbit testes (H&E stain). Control group showing seminiferous tubules (ST) including spermatogenesis with normal arrangement of spermatogenic cells with intact basement membrane (BM), lumen (L), sperm (S), Sertoli cells (St) blue arrow and Leydig cells (a x10, b x40). Gentamicin group (40 mg/kg bw) showing atrophic tubules (AT) disorganization and degeneration (D) of the spermatogenic cells, congested blood vessel (CBV), vacuolization (V), and apoptosis (c x10, d x10, e x40). Testosterone group showed normal architecture with a normal seminiferous tubule (f x10, g x40). Gentamicin + Testosterone treated rabbits showed tubular degeneration (D) (h x10, i x40).

Rabbits treated with gentamicin alone (GII) showed a marked elevation in serum FSH (0.32±0.08 mIU/ml, p<0.01) and LH (1.87±0.02 mIU/ml, p<0.05) compared with the control group. This pattern indicates primary testicular injury. Damage to the Leydig and Sertoli cells lowers testosterone and inhibin production. As a result, negative feedback on the hypothalamic-pituitary axis is lost, leading to a compensatory rise in gonadotropin secretion (Fusco *et al.,* 2021; Patel *et al*., 2019). Gentamicin-induced testicular oxidative damage, germ cell loss, and disruption of the pituitary-gonadal axis have been reported previously (Aly and Hassan, 2018; Taha *et al.,* 2022), although some studies have reported a fall in testosterone, FSH, and LH after gentamicin exposure (Taha *et al.,* 2022). This discrepancy may reflect differences in species, dose, and duration of exposure, as well as the stage of gonadal injury at which hormones were sampled; an initial compensatory hypergonadotropic phase may precede a later hypogonadotropic, exhaustion phase once Leydig cell reserve is depleted.

The present findings can be compared with recent studies investigating gentamicin-induced testicular toxicity. Celebi *et al.* (2026) reported reduced serum testosterone levels and sperm motility, together with increased lipid peroxidation, impaired antioxidant defenses, and enhanced apoptotic activity in gentamicin-exposed rats. Similarly, Badr *et al.* (2025) observed reduced testosterone and LH levels, accompanied by decreased testicular total antioxidant capacity and increased myeloperoxidase activity. Although these studies support the involvement of oxidative stress and testicular injury in gentamicin toxicity, differences in hormonal responses were evident. In the present study, gentamicin treatment increased both FSH and LH levels, suggesting that hormonal responses may vary according to the experimental model, dosage, and duration of exposure.

In contrast, rabbits treated with testosterone alone (GIII) showed significantly lower FSH (0.12±0.04mIU/ml, p<0.05) and LH (1.72±0.01 mIU/ml, p<0.05) levels than controls, along with tubular degeneration. This pattern is expected with exogenous androgens. High circulating testosterone suppresses GnRH, LH, and FSH through negative feedback on the hypothalamic-pituitary-gonadal axis, which in turn impairs spermatogenesis (Fusco *et al.*, 2021; Patel *et al.,* 2019**)**. However, serum testosterone does not always reflect intratesticular testosterone. Low LH reduces Leydig cell stimulation; therefore, intratesticular testosterone can fall even when serum levels are high. This could explain the tubular degeneration observed here despite testosterone treatment (Hashimi *et al.,* 2025). Similar degeneration, tubular atrophy, and oxidative damage have been reported with supraphysiological doses of testosterone and other anabolic steroids such as nandrolone decanoate (Karimi *et al.,* 2024). This suggests that the dose used in the present study (15 mg/kg bw) was above the physiological range and acted as a testicular toxicant rather than a protective agent.

The combination of testosterone followed by gentamicin (GIV) produced the highest FSH and LH levels among all groups, along with the most severe histopathological changes, including tubular amyloid deposition and tubular atrophy. This finding indicates that testosterone administration prior to gentamicin exposure exacerbated gonadal injury. This may be due to additive stress. Gentamicin generates reactive oxygen species and lipid peroxidation in testicular tissue (Aly and Hassan, 2018; Taha *et al*., 2023), and high-dose testosterone also promotes reactive oxygen species and inflammatory cytokine production. In this group, severe Leydig and Sertoli cell damage seemed to have overridden the expected suppressive effect of exogenous testosterone on gonadotropin secretion. This resulted in a hypergonadotropic profile, indicating primary gonadal failure rather than intact feedback regulation producing a hypergonadotropic hormonal profile that reflects primary

The present hormonal and histopathological results indicate that gentamicin disrupts testicular endocrine function and architecture, and that testosterone co-administration under the present experimental conditions does not ameliorate this toxicity but rather exacerbates it.

CONCLUSION

Gentamicin and testosterone, whether administered separately or in combination, induced significant disturbances in the testicular endocrine function and histological architecture of adult male rabbits. Gentamicin alone produced a hypergonadotropic hormonal pattern consistent with primary gonadal injury, testosterone alone suppressed gonadotropin secretion while still causing tubular degeneration, and their combination resulted in the most pronounced hormonal and structural damage. These findings do not support a protective role for testosterone against gentamicin-induced testicular toxicity under the conditions tested and instead suggest an additive detrimental effect. Caution is therefore warranted when gentamicin and androgen therapy are used concurrently, and further studies including additional hormonal and sperm functional endpoints with a recovery period could help confirm the mechanisms and reversibility.

CONFLICT OF INTEREST

The authors declare no conflicts of interest.

GENERATIVE AI STATEMENT

The author(s) declare that during preparation of this work, the first and corresponding author used Paperpal and AI to improve language and readability. After using this tool, the author reviewed and edited the content as needed and takes full responsibility for the content of the published article.

PUBLISHER'S NOTE

All claims expressed in this article are solely those of the authors and do not necessarily represent those of their affiliated organizations, or those of the publisher, the editors and the reviewers. The publisher does not guarantee or endorse any product that may be reviewed in this article or any claim made by its manufacturer.

REFERENCES

Abdelrahman, R.S., Abdelmageed, M.E., 2020. Renoprotective effect of celecoxib against gentamicin-induced nephrotoxicity through suppressing NF-κB and caspase-3 signaling pathways in rats. Chem. Biol. Interact., 315: 108863.

Aly, H.A., Hassan, M.H., 2018. Potential testicular toxicity of gentamicin in adult rats. Biochem. Biophys. Res. Com. Mun., 497(1): 362–367.

Ashraf, A., Iqbal, M.N., Iqbal, A., 2020. The Rise of Antibiotic Resistance in Clinical Isolates of Bacteria: An Emerging Public Health Problem. Int. J. Mol. Microbiol., 3(1): 15-7.

Iqbal, M.N., Ashraf, A., 2018. Ceftazidime Resistant Bacteria in Clinical Samples: Do We Need New Antibiotics?. Int. J. Mol. Microbiol., 1(2): 58-9.

Ashraf, A., Iqbal, M.N., 2020. Tracking the effectiveness of antibiotic therapy using the drug resistance profile of uropathogens in pregnant women. PSM Biol. Res., 5(4): 178-80.

Badr, N.S., Talaat, A., El-Saidy, S.A., Ghoneim, A.Z.A., 2025. Revealing Sarcophyton extract's alleviating potential against gentamicin-induced renal and testicular toxicity in rat model. J. Basic Appl. Zool., 86: 9.

Bancroft, J.D., Gamble, M., 2008. Theory and Practice of Histological Techniques. 6th Edition. Elsevier, China.

Baradaran, A., Nasri, H., Nematbakhsh, M., Rafeian-Kopaei, M., 2014. Antioxidant activity and preventive effect of aqueous leaf extract of aloe vera on gentamicin-induced nephrotoxicity in male Wistar rats. Clin. Ter., 165: 7–11.

Beaver, K. M., Vaughn, M.G., Delisi, M., Wright, J.P., 2008. Anabolic-androgenic steroid use and involvement in violent behavior in a nationally representative sample of young adult males in the United States. Am. J. Public Health, 98(12): 2185-2187.

Celebi, M., Celebi, C., Susar, H., Gungor, I.H., Karatas, O., 2026. Hesperidin attenuates gentamicin-induced testicular toxicity via modulation of the PI3K/AKT signaling pathway. BMC Complement. Med. Ther., 26: 261.

El-Sayyad, H.I., Ismail, M.F., Shalaby, F.M., Abou-El-Magd, R.F., Gaur, R.L., Fernando, A., et al. 2009. Histopathological effects of cisplatin, doxorubicin and 5-flurouracil (5-FU) on the liver of male albino rats. Int. J. Biol. Sci., 5(5): 466-473.

Fusco, F., Verze, P., Capece, M., Napolitano, L., 2021. Suppression of spermatogenesis by exogenous testosterone. Curr. Pharm. Des., 27(24): 2750–2753.

Hall, J.E., Hall, M.E., 2021. Guyton and Hall textbook of medical physiology (14th ed., pp. 1001-1020). Elsevier.

Hamad, S.R., Anwar, H.M., Diab, M.S., 2023. Assessment ameliorative role of fenugreek seeds and germinated fenugreek seeds on pancreatic and testicular gentamicin toxicity of male Swiss albino mice. J. Basic Appl. Zool., 84: 3.

Hartgens, F., Kuipers, H., 2004. Effects of androgenic-anabolic steroids in athletes. Sports Med., 34 (8): 513-554.

Hashimi, M.A., Pinggera, G.M., Shah R., Agarwal, A., 2025. Clinician's guide to the management of azoospermia induced by exogenous testosterone or anabolic-androgenic steroids. Asian J. Androl., 27(3): 330-341.

Herlitz, L.C., Markowitz, G.S., Farris, A.B., Schwimmer, J.A., Stokes, M.B., Kunis, C., et al. 2010. Development of focal segmental glomerulosclerosis after anabolic steroid abuse. J. Am. Soc. Nephrol., 21(1): 163-172.

Hong, S.H., Park, S.K., Cho, Y.S., Lee, H.S., Kim, K.R., Kim, M.G., Chung, W.H., 2006. Gentamicin induced nitric oxide-related oxidative damages on vestibular afferents in the guinea pig. Hear. Res., 211: 46–53.

Karimi, S., Kazori, N., Alavi, S.M.H., Alijanpout, S., Siddiqi, M.A.A., Zeynali, B., 2024. Nandrolone decanoate-induced hypogonadism in male rats: Dose- and time-dependent effects on pituitary and testicular hormonal functions. Physiol. Rep., 12: e70053.

Keogh, L.M., Byrne, P.G., Silla, A.J., 2017. The effect of gentamicin on sperm motility and bacterial abundance during chilled sperm storage in the booroolong frog. Gen. Comp. Endocrinol., 243: 51–59.

Khaki, A., Novin, M.G., Khaki, A.A., Fathiazad, F., Khabiri, M., Hossinchi, J., 2009. Ultra-structural study of gentamicin and ofloxacin effect on testis tissue in rats: Light and transmission electron microscopy. Afr. J. Pharm. Pharmacol., 3(4): 105-9.

Nieschlag, E., Vorona, E., 2015. Doping with Anabolic Androgenic Steroids (AAS): adverse effects on non-reproductive organs and functions. Rev. Endocr. Metab. Disord., 16(3): 199-211.

Patel, A.S., Leong, J.Y., Ramos, L., Ramasamy, R., 2019. Testosterone is a contraceptive and should not be used in men who desire fertility. World J. Men's Health., 37(1): 45–54.

Shokri, S., Hamadi, M., Bayat, G., Bahmanzadeh, M., Jafari-Anarkooli, L., Mashkani, B., 2014. Combination of running exercise and high dose of anabolic androgenic steroid. Nandrolone decanoate, increases protamine deficiency and DNA damage in rat spermatozoa. Andrologia, 46(2): 184-190.

Taha, M., Elazab, S.T., Saati, A.A., Ahmed, G.S., Baokbah, T.A., Fathy, K., et al. 2023. Zamzam water ameliorates gentamicin-induced testicular toxicity in a rat model via targeting sperm parameters, testicular tissue oxidative insult, inflammation, apoptosis, and pituitary-gonadal axis. Toxics, 11(1): 22.

Wu, C., Kovac, J.R., 2016. Novel uses for the anabolic androgenic steroids nandrolone and oxandrolone in the management of male health. Curr. Urol. Rep., 17: 72.